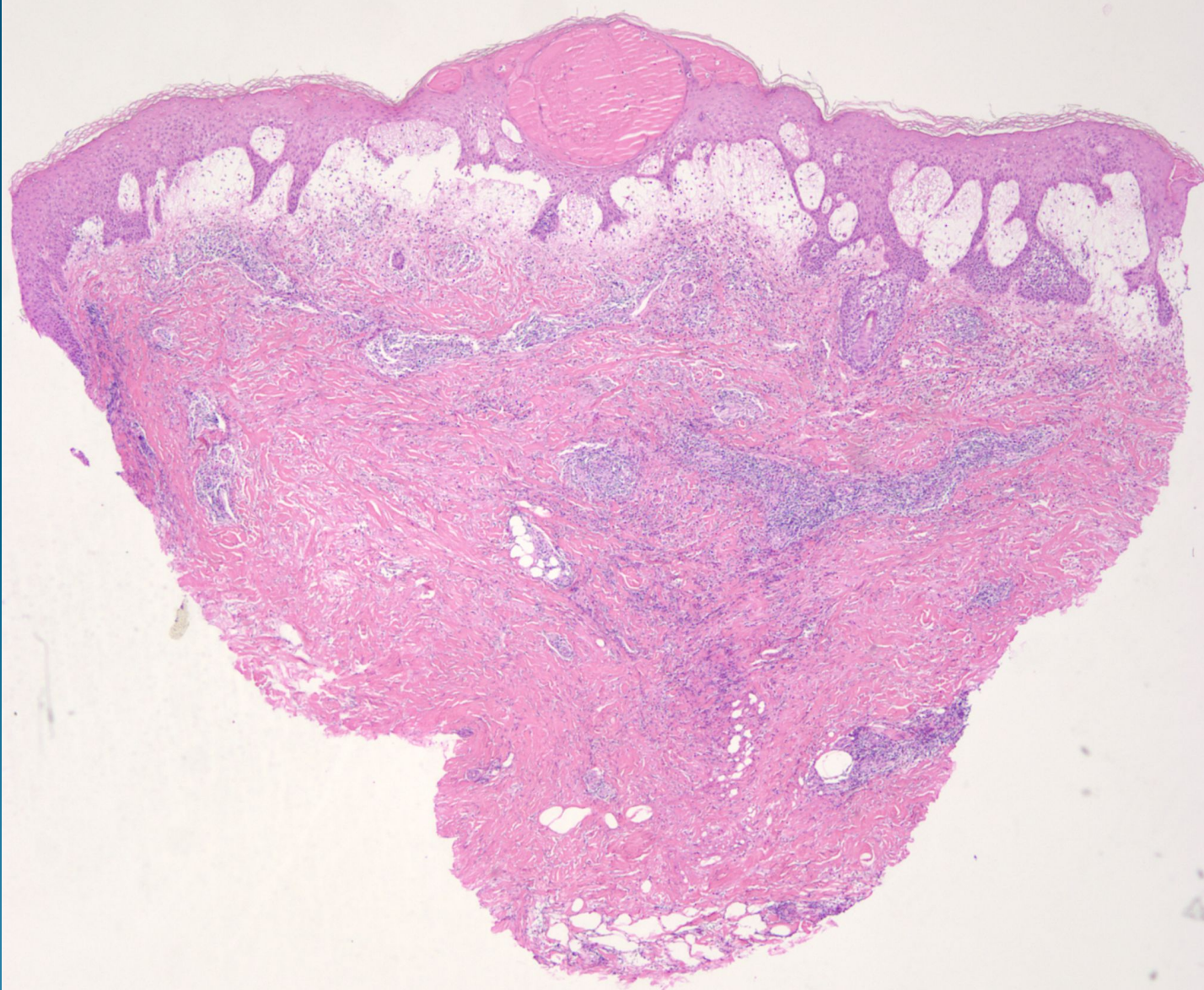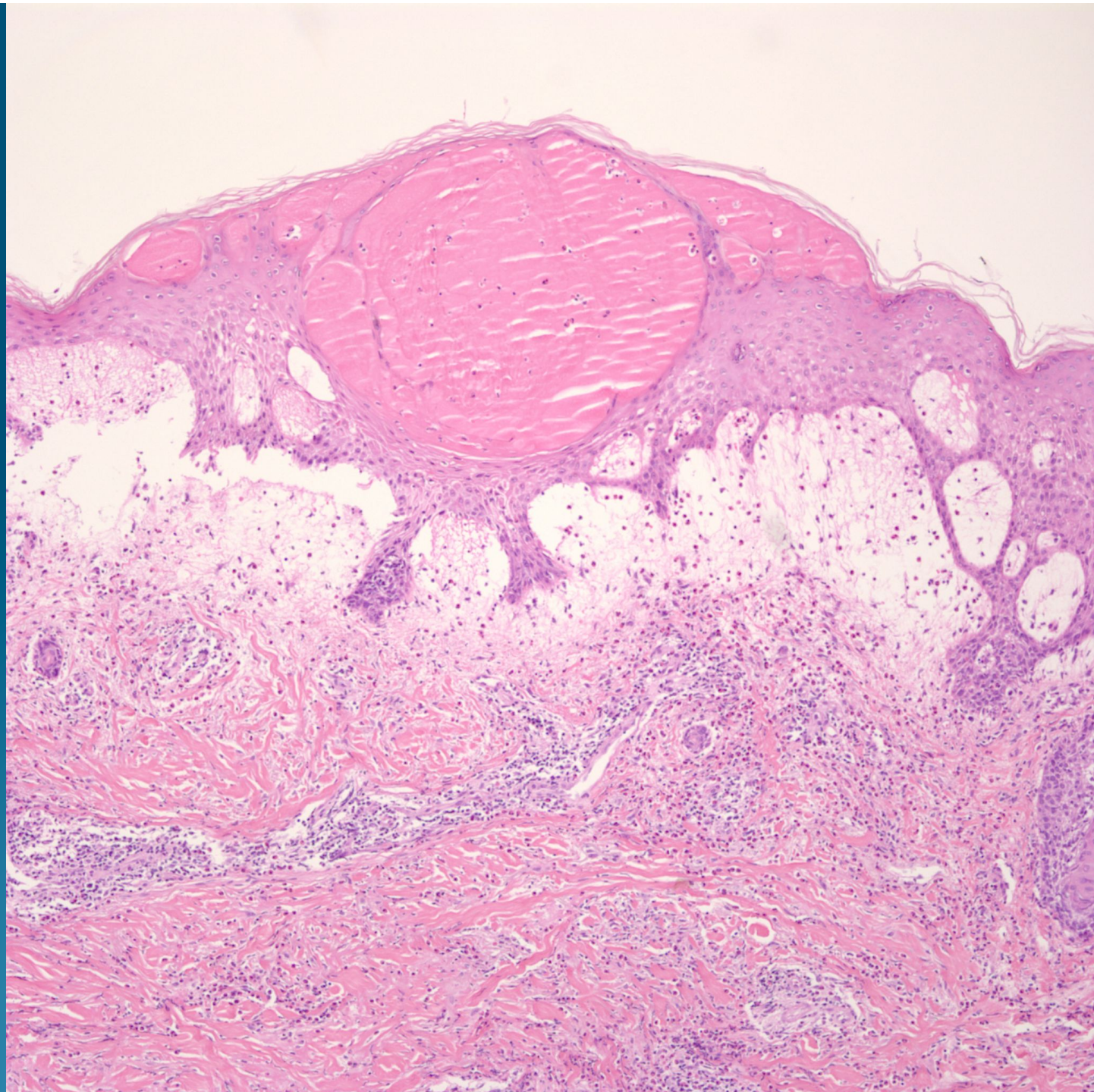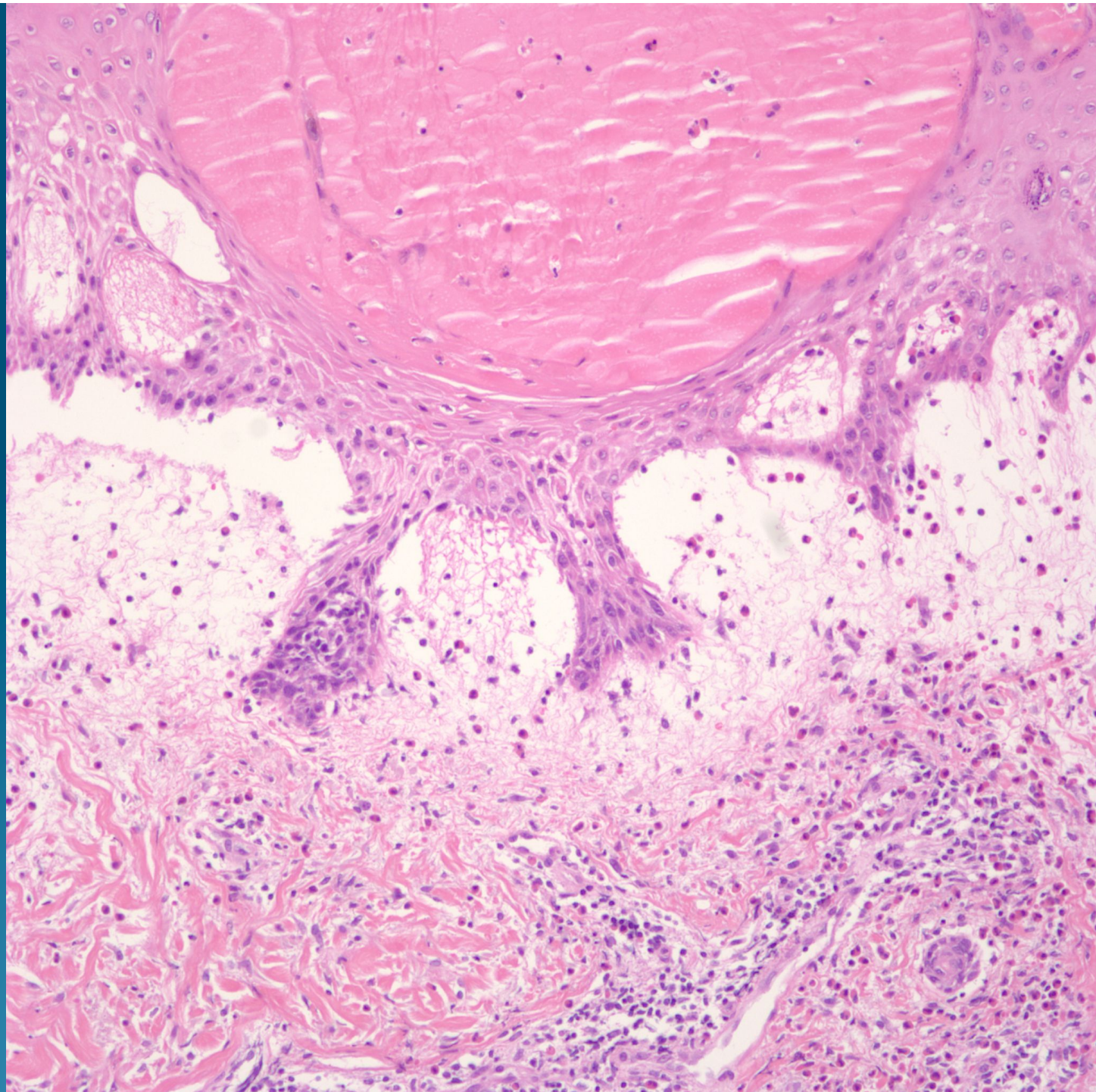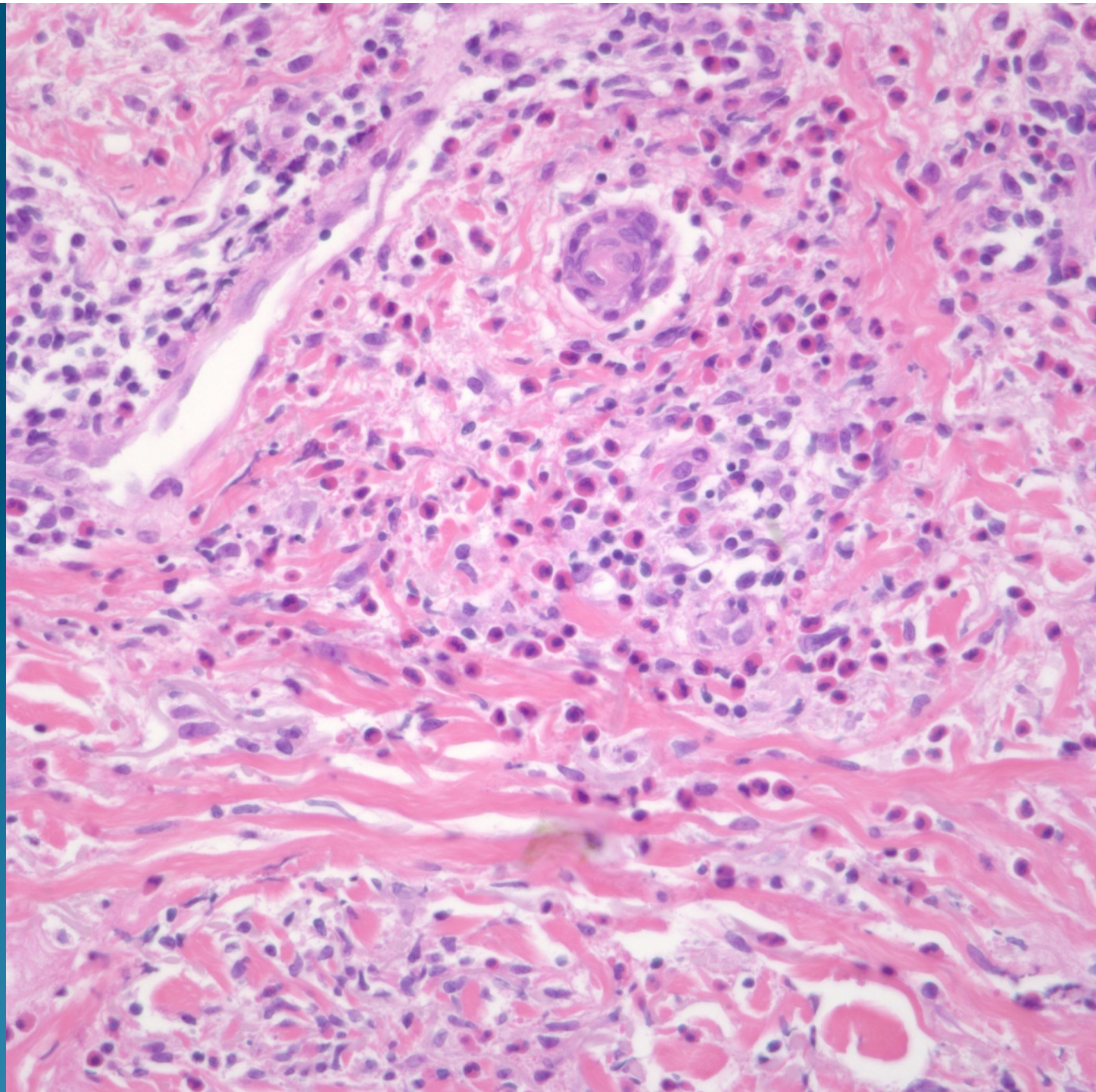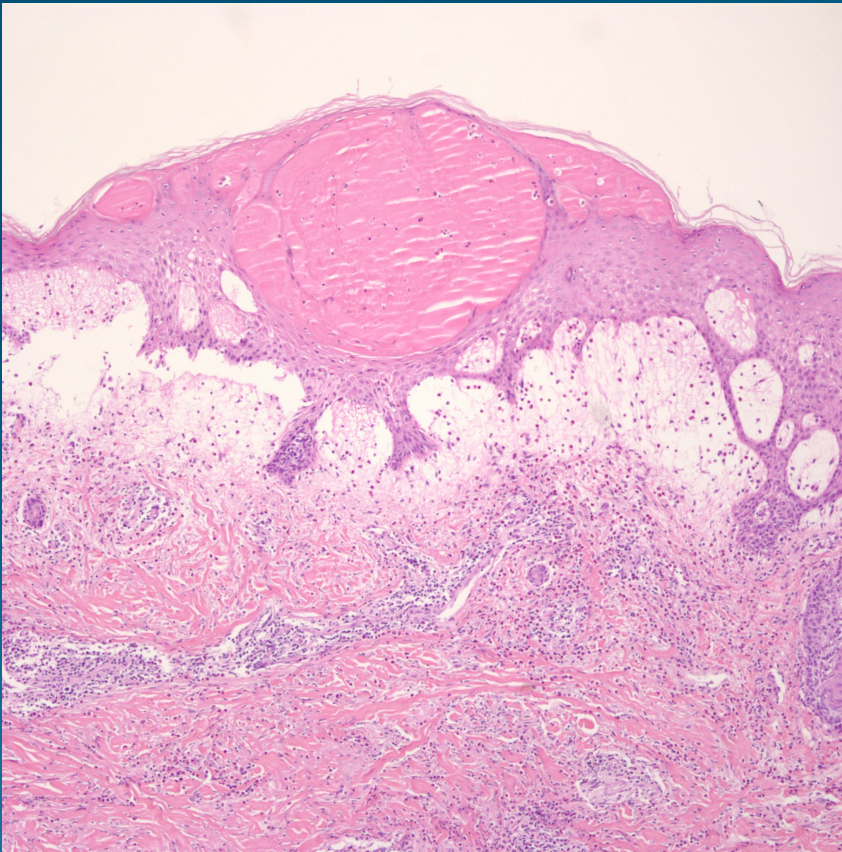


Changes Consistent with Arthropod Bite

Pearls



- Acute spongiotic dermatitis with eosinophils
- May be folliculocentric or wedge-shaped with apex in deeper dermis
- Variable edema and vesiculo-bullous changes